

Candida-associated denture stomatitis . Aetiology and management: A review. Part 2. Oral diseases caused by candida species

B. C. Webb*†
 C. J. Thomas†
 M. D. P. Willcox‡
 D. W. S. Harty*
 K. W. Knox*

Abstract

Certain systemic conditions and/or defects in the immune system may predispose the host to oral candidal infection and the commonest form of oral candidosis is candida-associated denture stomatitis. Until recently there has been controversy concerning the aetiology of the disease. Although some earlier investigators linked denture stomatitis with trauma or bacterial infection, others had isolated *Candida albicans* from the mouths of patients with the condition. Current studies indicate that denture stomatitis lesions are associated with the detection of candida species while other factors such as denture hygiene, trauma, systemic diseases and deficiencies of the immune system may be involved.

Key words: *Candida albicans*, acute pseudomembranous candidosis, acute atrophic candidosis, candida leukoplakia, candida-associated denture stomatitis, angular cheilitis.

(Received for publication January 1997. Revised April 1997. Accepted April 1997.)

Introduction

Much interest has been shown in the incidence of oral candidosis as it is frequently an early manifestation of HIV infection. Apart from these patients, however, oral candidosis in the form of candida-associated denture stomatitis is a common disease in some 65 per cent of denture wearers.¹ Other oral candidal infections of clinical significance include acute pseudomembranous candidosis (thrush), acute atrophic candidosis (antibiotic sore tongue), and angular cheilitis (perleche). There is an abundance of literature relating to candida infection within the oral cavity, but the review which follows is

orientated to the study of candida-associated denture stomatitis.

Oral diseases caused by candida species

Host reaction

The T-cell and macrophage mediated activation of the immune system are considered to be critical in the host defence mechanism against *Candida albicans*.² T-lymphocytes produce cytokines which elicit inflammation and the influx of polymorphonuclear neutrophils is the major factor in limiting the spread of infection. Consequently, defects in the cellular immune system predispose individuals to candida infections.² The study showed that four factors were involved in containing candidal infections: the stratum corneum must be intact, the host must generate complement-dependent chemotactic factors, the neutrophils must confine the infection and epidermal proliferation must occur to clear cutaneous candidosis.²

MacFarlane and Samaranayake³ noted that systemic conditions that may predispose individuals to oral candidosis included malnutrition, as it occurs in high carbohydrate diets, deficiencies in iron, folate or vitamin B12, hypoendocrine states such as hypothyroidism, Addison's disease (adrenocortical insufficiency), diabetes mellitus, blood disorders such as acute leukaemia, agranulocytosis, immune disorders such as HIV infection, thymic aplasia, xerostomia due to irradiation, drug therapy, cytotoxic drug therapy and Sjögren's syndrome (a group of symptoms including enlargement of the parotid gland).

The immuno-suppressive states that accompany treatment of malignancies and organ or bone marrow transplants result in changes in the oral

*Institute of Dental Research, Sydney.

†Faculty of Dentistry, The University of Sydney.

‡Cooperative Research Centre for Eye Research Technology, The University of New South Wales.

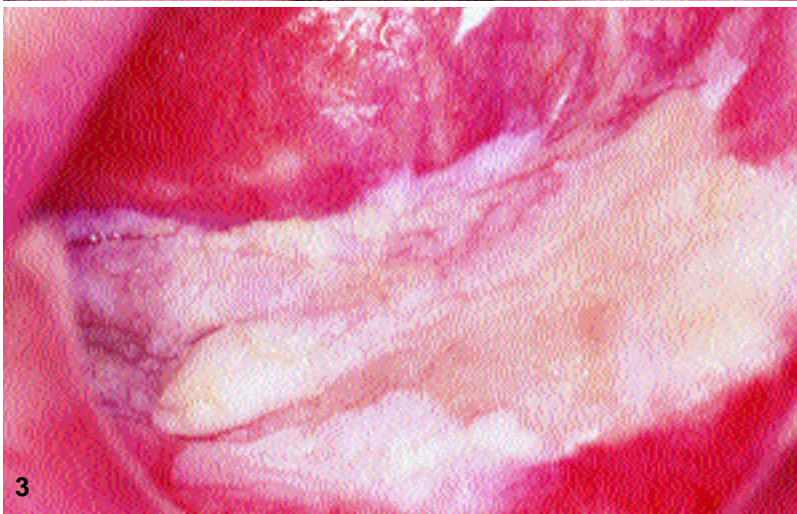
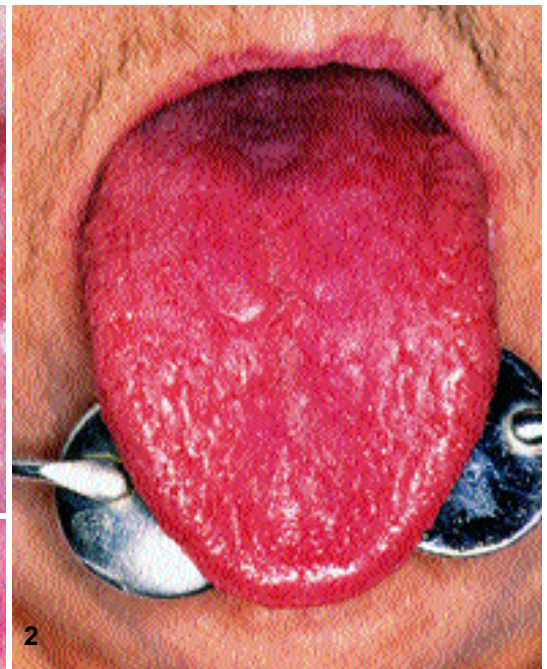
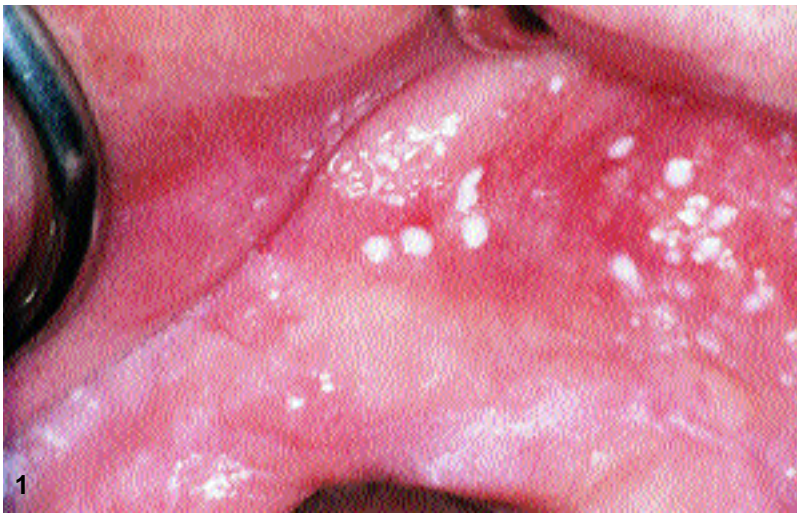
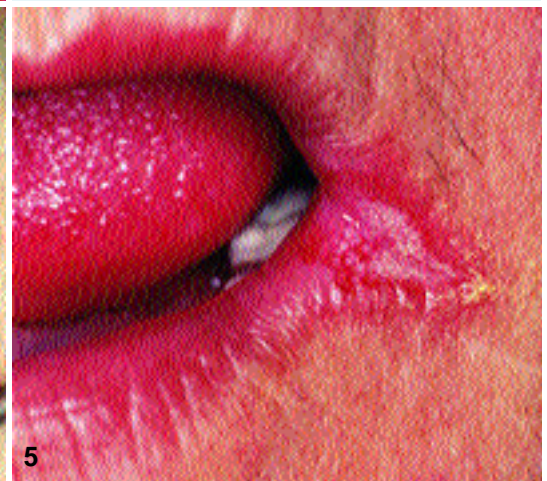
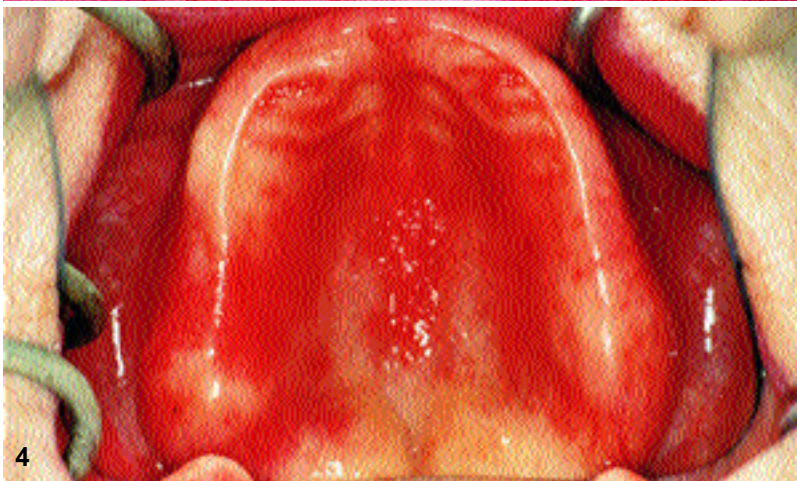Fig. 1.—Acute pseudomembranous candidosis showing edentulous upper anterior ridge and sulcus above with numerous colonies of *Candida albicans*.
 Fig. 2.—Acute atrophic candidosis showing dorsum of tongue with depapillation.
 Fig. 3.—Chronic hyperplastic candidosis showing floor of mouth and under-surface of tongue with 'heaped up' firm plaques.
 Fig. 4.—Chronic atrophic candidosis showing edentulous maxilla with inflamed mucosa of palate and upper posterior ridge.
 Fig. 5.—Angular cheilitis showing lesion at angle of mouth infected with thrush.



mucosa and oral microbiota which favour candida species colonization. Specific groups such as the very young, the very old and the pregnant are susceptible to oral candidal infections.^{3,4}

Acute pseudomembranous candidosis

Thrush or acute pseudomembranous candidosis occurs in 5 per cent of newborn infants and in 10 per cent of elderly debilitated individuals, and is one of the earliest and sometimes the initial manifestations of

AIDS. Clinically there is a creamy-white non-keratotic coating on the mucosa of the tongue, soft palate, cheek, gingiva or pharynx. The lesions vary from small discrete areas (Fig. 1) to confluent white patches covering a wide area and the coating is easily rubbed off to leave a red and slightly bleeding surface.³

Acute atrophic candidosis

Acute atrophic candidosis occurs with prolonged steroid or broad spectrum antibiotic therapy and is

known as antibiotic sore tongue or glossodynia. However, any part of the oral mucosa can be affected, including the buccal mucosa and the palate. When the tongue is involved, the dorsum shows marked depapillation (Fig. 2) and the affected areas become red, shiny and painful.³

Chronic hyperplastic candidosis

Chronic white patches on the oral mucosa characterize this lesion which is also known as candida leukoplakia and is indistinguishable from leukoplakia due to other causes. The plaques (Fig. 3), which are firm, whitish and speckled, and cannot be easily wiped off, usually appear as single lesions near the commissures or near the surface of the tongue.³

Chronic atrophic candidosis/candida-associated denture stomatitis

Denture induced stomatitis or chronic atrophic candidosis is the commonest form of oral candidosis and is present in 24-60 per cent of denture wearers; it may also be associated with orthodontic appliances and obturators. The condition is usually found on the palatal mucosa (Fig. 4) beneath the fitting surface of the upper denture and both complete and partial denture wearers are affected. It is unusual for the condition to occur on the lower denture bearing mucosa.³

Denture stomatitis has been associated with angular cheilitis, atrophic glossitis, acute pseudo-membranous candidosis and chronic hyperplastic candidosis, and has been found to be more common in females than males. The condition is frequently symptomless, but when signs and symptoms are present they may display mucosal bleeding, swelling, burning or other painful sensations, halitosis, unpleasant taste and dryness in the mouth.⁵

Denture stomatitis may be classified according to the clinical appearance of the inflamed mucosa under the maxillary complete denture, and includes three types.⁶ Type I refers to the initial stage of localized pin-point hyperaemia while Type II, which is the most common type of denture stomatitis, is described as having diffuse erythema and oedema of the denture-bearing areas of the palatal mucosa. The affected area is confined to the denture-bearing surface and is demarcated at the margins of the denture; the condition is not painful and can be associated with angular cheilitis. If Type II is untreated for a prolonged period it has been said that Type III may develop, in which a hyperplastic reaction occurs resulting in a nodular lesion of the central palate often with associated atrophic areas, and this is referred to as papillary hyperplasia. The view of Thomas *et al.*,⁷ however, is that papillary hyperplasia may form independently and that it may

occur in subjects with a genetically sourced papillated palatal mucosa with a superimposed denture stomatitis. All three types may be found simultaneously and in varying combinations.

Budtz-Jorgensen and Bertram⁸ classified denture stomatitis according to the type of inflammation observed on the mucous membrane of the palate under a maxillary denture. There were three classifications, simple localized inflammation (involving a limited area), simple diffuse inflammation (involving the whole area covered by the denture) and granular inflammation (often localized to the central part of the hard palate).

Bergendal and Isacsson⁹ followed Ostlund's¹⁰ classification and used the term local inflammation to describe red spots usually found around the small palatal minor salivary glands; the lesion was thought to be associated with trauma from the dentures. The term diffuse reddening referred to a diffuse hyperaemic, smooth and atrophic mucosa extending over the entire denture area and was associated with increased growth of yeasts. The third type of denture stomatitis was described as granulated and was characterized by hyperaemic mucosa with a nodular appearance in the central part of the palate and both trauma and candida infection have been linked with this lesion.

The literature contains a large amount of data relating to the cause of denture stomatitis and these are discussed in the following sections.

Trauma

Nyquist¹¹ considered that trauma caused by dentures was the dominant factor in the occurrence of denture stomatitis ('sore mouth'), and he found no association between denture stomatitis and the bacterial microbiota under complete upper dentures. Cawson¹² found no convincing evidence that denture stomatitis was caused by trauma from the denture, or hypersensitivity to denture base material but in later studies it was concluded that the significant causes of denture stomatitis were trauma and infection with candida species.¹³ The studies indicated that the localized simple type of denture stomatitis (mentioned previously) was caused by trauma from ill-fitting dentures and would be resolved after proper adjustment of the dentures.

Bacteria

Nyquist¹¹ observed that there was no significant difference between the numbers of bacteria counted in cases of denture sore mouth and clinically normal mucosa and also no difference in the types of bacteria. The number of bacteria was generally characteristic of the individual, and there was a significant trend towards larger aerobic than anaerobic populations for any one individual. However, the

study showed that the bacteria increased in number when the denture was worn for a longer period. A larger population of aerobic bacteria for a 'rubber' (Vulcanite) denture than for an acrylic denture was observed although there was no significant difference for the anaerobic population and there was no difference between the types of bacteria occurring in cases of denture stomatitis associated with 'rubber' and acrylic dentures. The most common type of bacteria isolated was *Neisseria (Branhamella) catarrhalis*, with *Staphylococcus albus (epidermidis)* (coagulase negative staphylococcus) next in order of frequency, but streptococci and other types of bacteria were sparsely represented. This spectrum of bacteria is unusual, but may reflect the methods of isolation and identification in use over 40 years ago.

In contrast to these findings,¹¹ van Reenen's studies¹⁴ have given prominence to the role of bacteria in denture stomatitis. The numbers of Gram-positive cocci including streptococci, pneumococci and staphylococci were more frequently isolated from the palatal mucosa of patients with denture stomatitis, the author suggesting that no specific organism was associated with denture stomatitis lesions and that the infection was caused by a community of pathogens. The study showed that most bacteria isolated from denture stomatitis lesions were able to adhere to palatal epithelial cells and that in subjects who did not wear dentures, there was a relative absence of bacteria on the palatal mucosa compared with similar observations in denture wearers.

Candida species

One of the earliest studies associating yeast-like organisms with 'denture sore mouth' was that of Cahn¹⁵ who found *Monilia (Candida) albicans* in four patients with compromised health. Both Cahn¹⁵ and co-investigator Bartels¹⁶ were very cautious in their conclusions and emphasized that not all cases of denture stomatitis were due to infection by yeast-like organisms. The patients were successfully treated with 5 per cent aqueous solution of gentian violet and they kept their dentures in hypochlorite overnight.

A report on the frequency of isolation of yeast species from various human sites over a two-year period disclosed that the frequency of isolation from the oral cavity was 71 per cent and included specimens from the pharynx, tonsils, gingiva and tongue as well as sputum.¹⁷ The two species most frequently isolated were *C. albicans* and *Torulopsis glabrata (Candida glabrata)* and together they formed 87 per cent of all the species from the oral cavity. The study showed that *C. albicans* could be considered as part of the normal microbiota in the human body since it was isolated so frequently, and *Candida krusei*,

Candida tropicalis, *Candida pseudotropicalis (Candida kefyr)* and *Candida parapsilosis* were also isolated.¹⁷

An early study by Cawson¹² on denture stomatitis included a number of important observations: candida were isolated much more frequently from cases of denture stomatitis than from healthy denture wearers and the predominant species was *C. albicans*. Three methods were used to isolate candida from patients with denture stomatitis, namely, direct smear from the mucosa, culture of a swab from the mucosa and imprint culture directly from the denture; although candida was isolated from a palatal swab, a saliva specimen was considered to be more sensitive. Hyphae were present as the predominant or only form in most cases of denture stomatitis from which candida had been isolated and it was concluded that hyphae were actively growing in the potential space between denture and mucosa and when the denture is worn continuously it eliminates the cleansing effects of tongue, saliva and any antibodies in the saliva. It was emphasized that sampling of the denture-bearing area must take place immediately after the denture is removed as once the mucosa is exposed to the cleansing effect of saliva and tongue movements the microorganisms are easily dislodged, resulting in an inaccurate reading.

Cawson¹² noted that thrush occasionally developed in association with denture stomatitis and he referred to the 'infective origin' of denture stomatitis in close association with angular cheilitis. It was affirmed that angular cheilitis in denture stomatitis patients was not just a mechanical problem with loss of vertical dimension resulting in the characteristic fold at the angle of the mouth but rather an infection derived from a primary source. This theory was confirmed when treatment of denture stomatitis with antifungals resulted in resolution of angular cheilitis without any specific treatment for the latter condition. It was also shown that nystatin and amphotericin B in the form of tablets dissolved in the mouth were effective in the treatment of denture stomatitis, and it was emphasized that the medication should be applied topically so that the infected area was exposed to the drug while the dentures were removed during treatment.

In an examination of fifty denture stomatitis patients it was found that greater numbers of candida cells were recovered from smears prepared from the fitting surface of upper dentures than from those of the palatal mucosa,¹⁸ and this was in agreement with the studies of van Reenen¹⁴ and Budtz-Jorgensen.¹⁹ It was concluded that denture stomatitis was associated with the growth of candida within the plaque on the denture rather than on the palatal mucosa, and it was suggested therefore that treatment be directed to the denture in preference to the mucosa.¹⁸

Later a method for the site-specific detection of *C. albicans* on the denture surface was developed and

the distribution of yeast species was correlated with the severity of the denture stomatitis lesions.²⁰ The study was based on previous findings which showed that *C. albicans* was isolated more frequently from the denture fitting surface than from the corresponding mucosa.²¹⁻²³ The agar replica system was employed with an amino acid selective synthetic growth medium for *C. albicans*, supplemented with arginine, zinc sulphate and Bacto-agar. The results showed that the severity of palatal inflammation correlated with the number of *C. albicans* colonies on the agar replica, with the greatest number of colonies being observed in patients with Newton type III lesions. However, this clinical correlation was not noted in patients with Newton type I and II lesions. In explaining these findings it was pointed out that there was a lack of knowledge concerning the specific aetiology of denture stomatitis.²⁰

Budtz-Jorgensen¹³ considered that most of the lesions of the generalized simple or granular type of denture stomatitis associated with angular cheilitis or glossitis seemed to be induced by candida species. In common with other findings¹² the author established that candida species were cultured more frequently and in greater numbers in cases of denture stomatitis than in healthy denture wearers, *C. albicans* being the most common species. A palatal smear yielding mycelium or pseudohyphae was considered to be sufficient evidence of candida-induced denture stomatitis, and the importance of scraping both palate and denture was emphasized. The author concluded that since no mycelia were observed in scrapings from the local simple lesions, the latter could not be induced by *C. albicans*.

Trauma and candida species

Budtz-Jorgensen¹³ considered that treatment of the local simple lesion should include the construction of new properly fitting dentures and the use of tissue conditioners, but the candida-induced lesions were unaffected by prosthetic intervention. Since the dentures seemed to provide an ideal environment for candida growth and infection, it was found that removal of the dentures was essential during the treatment period even if this was socially unacceptable to some.^{12,13}

Denture lining materials

Denture lining materials, which include tissue conditioners and soft denture liners, are widely used as adjuncts in the prosthodontic treatment and management of traumatized oral mucosa, and are most commonly used in association with the mandibular denture. Tissue conditioners are used to assist denture bearing tissues recover from trauma often due to ill-fitting dentures and consist of polyethyl methacrylate polymers with a plasticizer and

ethyl alcohol. Resilient or soft denture liners are used on the fitting surfaces of dentures when the patient presents with problems such as sharp or irregular ridges, tissue defects, or thin non-resilient oral mucosa. Current materials are either silicone elastomers, plasticized higher methacrylate polymers, hydrophilic polymethacrylates or fluoropolymers.

Soft-lined mandibular dentures have been associated with candidal growth and it has been reported that candida species were detected in 85 per cent and 44 per cent of lined mandibular and unlined maxillary dentures respectively.²⁴ The most commonly detected yeasts were *C. albicans*, *C. glabrata* and *C. tropicalis*. It was also demonstrated that Molloplast B§ had no inhibitory effect on candidal growth *in vivo* but *in vitro* the uncured material caused a definite inhibition of candida growth whereas the cured material did not indicate any such inhibition.²⁴

However, in another study it was found that increased isolation frequency of yeasts on the fitting surface of mandibular dentures lined with either Molloplast B or the tissue conditioner Visco-gel, was not associated with an increased inflammatory response of the mandibular denture-bearing mucosa.²⁵ The study showed that *C. albicans* was the most frequently isolated of the candida species associated with soft denture liners.

Graham *et al.*²⁶ tested two tissue conditioners Veltec¶ and Coe-Comfort** *in vivo* and found that both materials supported the presence and growth of *C. albicans*, though there was no significant difference in the prevalence of candida species between the two materials tested.

In a study of the adherence of *C. albicans* to soft denture-lining materials including Coe-Comfort, Visco-gel and Coe-Soft** it was found that factors other than hydrophobic action, for example, specific interaction, may be involved in fungal adherence to saliva-coated soft denture liners.²⁷ In another study the authors showed that denture pellicle (plaque) potentiates *C. albicans* colonization and hyphal invasion of denture-lining material and may therefore be a factor in promoting denture stomatitis.²⁸

Candida species and other oral microorganisms

The work of Fouché *et al.*²⁹ drew attention not only to candida species as the causative organism in denture stomatitis but also concentrated on the role played by other oral microorganisms. The study identified to species level the aerobic microorganisms isolated from a group of subjects with Newton's type II and III denture stomatitis. The results showed

§Detax Dental, Karl Huber, Ettlingen, Germany.

¶De Trey Division, Dentsply Limited, Weybridge, Surrey, England.

**Teledyne, Elk Grove Village, Illinois, USA.

**Coe Laboratories, Inc., Chicago, Illinois, USA.

that *C. albicans* was recovered from all participants with one exception when *C. tropicalis* was detected. Three species of lactobacilli, *Lactobacillus acidophilus*, *Lactobacillus brevis* and *Lactobacillus salivarius*, and seven species of streptococci, designated *Streptococcus bovis*, *Streptococcus mitis*, *Streptococcus mutans*, *Streptococcus pneumoniae*, *Streptococcus salivarius* and *Streptococcus sanguis* I and II, were isolated. *Micrococcus luteus*, *Micrococcus varians* and *Staphylococcus epidermidis* were also recovered. The only Gram-negative microorganisms isolated were *Haemophilus influenza* and *Neisseria meningitidis*.²⁹

Denture hygiene/denture plaque

Nyquist¹¹ investigated the influence of denture hygiene on inflammation of the soft tissues under complete upper dentures and found no evidence that frequency or method of denture cleansing had any effect on the incidence of denture sore mouth. Cleansing of the oral mucosa twice a day was also ineffective.

The porosity and surface texture of acrylic resin were investigated,²² and it was found that the denture surface was of fine texture with an absence of porosity. This did not allow attachment of plaque by penetration of surface defects or by mechanical fixation to surface irregularities. It was recommended therefore that microbial plaque on the denture be removed by simple denture hygiene measures such as careful brushing and, as a useful adjunct, 0.1% aqueous chlorhexidine over-night denture soak.²²

Lack of denture cleanliness is considered to be one of the factors involved in the aetiology of denture stomatitis and the need to remove denture plaque at regular intervals, especially on the tissue fitting surfaces of dentures was emphasized. The study demonstrated that when a rigorous denture cleansing regimen was followed, previous denture brushing habits were shown to be totally inadequate.³⁰

Schou *et al.*³¹ have shown that there is a significant relationship between plaque formation, soaking habits with substances such as alkaline peroxide and the presence of denture stomatitis. However, it was not shown that denture plaque was related to brushing habits or candidal growth. On the other hand, Iacopino and Wathen³² noted the presence of *C. albicans* in microbial denture plaque and emphasized the importance of oral hygiene.

Permeability of acrylic resin

Contrary to Davenport's findings,²² van Reenen¹⁴ showed *in vitro* that *C. albicans* penetrated the commonly used acrylic resin which was confirmed with the use of a fluorescent dye and *C. albicans*.³³ Penetration of the unpolished surface, which is in contact with the mucosa, was greater than that of the polished surface. It was suggested that the unpolished

surface of the denture was a suitable site for candida proliferation and sealing of the surface was recommended. The effect of acrylic resin on the pH of glucose broth inoculated with *C. albicans* was also studied and it was found that acrylic resin alone did not alter the pH. However, acrylic resin together with *C. albicans* raised the pH and *C. albicans* alone lowered the pH. It was considered possible that a similar interaction between acrylic resin and *C. albicans* could take place in the mouth and the rise in pH could create a favourable environment between denture and mucosa for the growth of microorganisms.³³

Antibodies and immunological factors

Lehner³⁴ found that the antibody titre to candida from serum and saliva by fluorescent antibody technique was significantly higher in patients with denture stomatitis than in healthy denture wearers.

van Reenen¹⁴ considered that a low serum antibody titre to *C. albicans* compared with that to other oral pathogens, was an indication that the yeast was not principally involved in denture stomatitis lesions but that the disease was a mixed infection. However, the studies of Iacopino and Wathen³² demonstrated that antibodies to *C. albicans* occur later than those to other pathogens, and this may explain why in van Reenen's study¹⁴ significant titres of serum antibodies to *C. albicans* were not found. It was also suggested that since the oral mucosa is protected by salivary IgA, this antibody may play an important role in the defence against oral candidosis.³²

Denture stomatitis rarely occurs without at least one predisposing factor that lowers patient resistance and Iacopino and Wathen³² have presented their immunological theory of patient susceptibility. It was observed that candidal infection resulted in both cell mediated immunity (CMI) and humoral immune responses, with CMI providing protection against superficial candidal infection. It was concluded that patients with denture stomatitis who do not suffer any CMI defects may be deficient in migration inhibition factor and may have overactive suppressor T-cells or other T-lymphocyte/phagocyte defects and such immunological factors may predispose the patient to denture stomatitis.

Multifactorial findings

The cause of denture stomatitis is now believed to be multifactorial, and it has been considered that the following factors are significant: denture trauma, continuous denture wearing, denture cleanliness, dietary factors, candida infections and predisposing systemic conditions.⁵ It is generally regarded that candida species, in particular *C. albicans*, are the causative agents of denture stomatitis, although the above mentioned factors and denture plaque bacteria may be involved.

Angular cheilitis

Angular cheilitis (angular stomatitis/perlèche) is frequently a complication of chronic atrophic candidosis, although it can be associated with any type of oral candidosis (Fig. 5). Infection is by candida and/or staphylococci, streptococci and other organisms and can be a varying combination of all. The usual endogenous reservoirs of these organisms are the oral cavity and the anterior nares. Beta-haemolytic streptococci, particularly Lancefield Group B, are sometimes identified. Other factors involved in the aetiology of angular cheilitis are iron deficiency anaemia, vitamin B12 deficiency, inadequate vertical dimension of occlusion in dentures, and skin creasing at the angles of the mouth due to ageing. Angular cheilitis is also a common oral manifestation of AIDS.³

Summary

The oral diseases caused by candida species have been reviewed in this paper and particular attention given to the multifactorial aetiology of candida-associated denture stomatitis. Part 3 of this review will be concerned with the treatment of oral candidosis.

Acknowledgements

This study was supported by a research grant from the Faculty of Dentistry, University of Sydney. The provision of clinical photographs by Emeritus Professor Mark Jolly (formerly McCaughey Professor of Oral Medicine and Oral Surgery, University of Sydney) and Associate Professor C. J. Thomas (Faculty of Dentistry), is gratefully acknowledged.

References

1. Budtz-Jorgensen E, Stenderup A, Grabowski M. An epidemiologic study of yeasts in elderly denture wearers. *Community Dent Oral Epidemiol* 1975;3:115-9.
2. Shepherd MG. The pathogenesis and host defence mechanisms of oral candidosis. *NZ Dent J* 1986;82:78-82.
3. MacFarlane TW, Samaranayake LP. Fungal infections. In: *Clinical Oral Microbiology*. London: Wright, 1989:122-39.
4. Epstein JB. Oral and pharyngeal candidiasis. Topical agents for management and prevention. *Postgrad Med* 1989;85:257-69.
5. Arendorf TM, Walker DM. Denture stomatitis: a review. *J Oral Rehabil* 1987;14:217-27.
6. Newton AV. Denture sore mouth. A possible aetiology. *Br Dent J* 1962;112:357-60.
7. Thomas CJ, Kotze JvW, Nash JM. Papillarity of the palatal mucosa. *J Oral Rehabil* 1985;12:491-7.
8. Budtz-Jorgensen E, Bertram U. Denture stomatitis 1. The etiology in relation to trauma and infection. *Acta Odontol Scand* 1970;28:71-92.
9. Bergendal T, Isacson G. A combined clinical, mycological and histological study of denture stomatitis. *Acta Odontol Scand* 1983;41:33-44.
10. Ostlund SG. The effect of complete dentures on the gum tissues. *Acta Odontol Scand* 1958;16:1-43.
11. Nyquist G. The influence of denture hygiene and the bacterial flora on the condition of the oral mucosa in full denture cases. *Acta Odontol Scand* 1953;11:Supplement 1:24-60.
12. Cawson RA. Denture sore mouth II. The role of candida. *The Dental Practitioner* 1965;16:138-42.
13. Budtz-Jorgensen E. The significance of *Candida albicans* in denture stomatitis. *Scand J Dent Res* 1974;82:151-90.
14. van Reenen JF. Microbiologic studies on denture stomatitis. *J Prosthet Dent* 1973;30:493-505.
15. Cahn LR. The denture sore mouth. *Ann Dent* 1936;3:33-6.
16. Bartels HA. Significance of yeast-like organisms in denture sore mouth. *Int J Orthod Oral Surg* 1937;23:90-3.
17. Stenderup A, Pedersen GT. Yeasts of human origin. *Acta Pathol Microbiol Scand* 1962;54:462-72.
18. Davenport JC. The oral distribution of candida in denture stomatitis. *Br Dent J* 1970;129:151-6.
19. Budtz-Jorgensen E. Candida-associated denture stomatitis and angular cheilitis. In: Samaranayake LP, MacFarlane TW, eds. *Oral candidosis*. London: Butterworth, 1990:156-83.
20. Santarpia III RP, Pollock JJ, Renner RP, Spiechowicz E. An *in vivo* replica method for the site-specific detection of *Candida albicans* on the denture surface in denture stomatitis patients: Correlation with clinical disease. *J Prosthet Dent* 1990;63:437-43.
21. Bahn AN, Quillman PD, Kendrick FJ. Intraoral localization of microorganisms. *J Dent Res* 1962;41:715.
22. Davenport JC. The denture surface. *Br Dent J* 1972;133:101-5.
23. Santarpia III RP, Renner RP, Pollock JJ, Gwinnet AJ, Brandt EC. Model system for the *in vitro* testing of a synthetic histidine peptide against candida species grown directly on the denture surface of patients with denture stomatitis. *J Prosthet Dent* 1988;60:62-70.
24. Makila E, Hopsu-Havu VK. Mycotic growth and soft denture lining materials. *Acta Odontol Scand* 1977;35:197-205.
25. Wright PS, Clark P, Hardie JM. The prevalence and significance of yeasts in persons wearing complete dentures with soft-lining materials. *J Dent Res* 1985;64:122-5.
26. Graham BS, Jones DW, Burke J, Thompson JP. *In vivo* fungal presence and growth on two resilient denture liners. *J Prosthet Dent* 1991;65:528-32.
27. Nikawa H, Iwanaga H, Kameda M, Hamada T. *In vitro* evaluation of *Candida albicans* adherence to soft denture-lining materials. *J Prosthet Dent* 1992;68:804-8.
28. Nikawa H, Hayashi S, Nikawa Y, Hamada T, Samaranayake LP. Interactions between denture lining material, protein pellicles and *Candida albicans*. *Arch Oral Biol* 1993;38:631-4.
29. Fouché MH, Slabbert JCG, Coogan MM. Microorganisms isolated from patients with denture stomatitis. *J Dent Assoc S Afr* 1986;41:313-6.
30. Tarbet WJ. Denture plaque: Quiet destroyer. *J Prosthet Dent* 1982;48:647-52.
31. Schou L, Wight C, Cumming C. Oral hygiene habits, denture plaque, presence of yeasts and stomatitis in institutionalised elderly in Lothian, Scotland. *Community Dent Oral Epidemiol* 1987;15:85-9.
32. Iacopino AM, Wathen WF. Oral candidal infection and denture stomatitis: A comprehensive review. *J Am Dent Assoc* 1992;123:46-51.
33. Levin AC. *Candida albicans* and acrylic resin. *J Dent Assoc S Afr* 1973;28:216-20.
34. Lehner T. Denture sore mouth III. Immunofluorescent investigation of candida. *Dent Pract* 1965;16:142-6.

Address for correspondence/reprints:

Dr B. C. Webb,
Institute of Dental Research,
2 Chalmers Street,
Surry Hills, New South Wales 2010.